

# Macrophage depletion diminishes UHMWPE particle- induced inflammatory osteolysis in a mouse model

Yunhong Ding, Xing Peng, Bin Wu, Paul H. Wooley, Reto Schwendener\* and Weiping Ren  
Department of Orthopedic Surgery, Wayne State University, Detroit, MI 48201  
\* Division of Molecular Cell Biology, Paul Scherrer Institute, Switzerland

**Introduction:** Aseptic loosening (AL) is the most common cause of implant failure. Implant wear- induced macrophage activation and recruitment to periprosthetic tissue has been proposed to contribute to the pathogenesis of AL. The purpose of this study was to determine whether treatment with clodronate liposomes (CL2MDP), which causes macrophage depletion, diminishes ultra high molecular weight polyethylene (UHMWPE) particle- induced inflammatory osteolysis in a mouse osteolysis model.

**Methods:** Air pouches were established by injection of sterile air on the back of BALB/c mice, followed by introduction of 0.5 ml of UHMWPE (5 mg/ml). One day later, a section of calvaria from a syngeneic mouse was inserted into the pouch. Macrophages were depleted by use of CL2MDP intraperitoneally (1 mg) 1 day before and every 2 to 3 days after bone implantation. Mice were randomly assigned to four experiment groups with 10 animals in each group: (1) Saline injection; (2) UHMWPE injection; (3) UHMWPE injection + empty liposome, and (4) UHMWPE + CL2MDP. Tissues were harvested 14 days after bone implantation for morphological and molecular analysis.

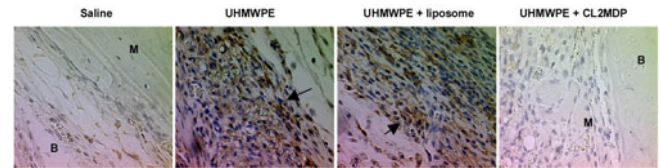
The images of H&E stain of pouch membrane were analyzed using an image analysis system including membrane thickness and the number of total infiltrated cells. Osteoclast activity was determined by tartrate-resistant acid phosphatase (TRAP) staining in paraffin tissue sections.

Statistical analysis between groups was performed using the ANOVA test, with the Schafer formula for *post hoc* multiple comparisons, using the SPSS software package (version 7.5), and the significance was determined by the Students T-test.

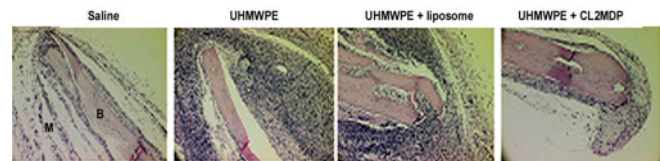
**Results:** F4/80 immunostaining confirmed the effective depletion of pouch tissue in CL2MDP-treated mice, as shown in figure 1. We observed the similar findings in both spleen and liver tissue sections (data not shown). Image analysis of H&E stained tissue sections showed that both the membrane thickness ( $125 \pm 28 \mu\text{m}$ ) and the cellular infiltration ( $6173 \pm 4378 \text{ mm}^2$ ) of the pouch membrane in CL2MDP-treated mice were significantly decreased in comparison with untreated mice ( $220 \pm 30 \mu\text{m}$  and  $16925 \pm 1635 \text{ mm}^2$  respectively, both  $p < 0.01$ ). (figure. 2). Osteoclast activity was determined by TRAP staining on paraffin tissue sections. As shown in Figure 3, in untreated mice, a large number of TRAP<sup>+</sup> cells were found both in the implanted calvaria, and at its contact site with inflammatory tissue, where high levels of active

osteolysis was observed. CL2MDP treatment caused a significant reduction in the number of TRAP<sup>+</sup> cells.

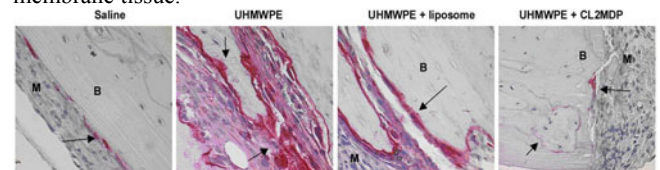
**Figure 1.** F4/80 staining performed on pouch tissue sections. B, implanted bone; M, pouch membrane tissue. F4/80<sup>+</sup> cells showed granular brown staining, as shown by arrows. Notice surrounding UHMWPE particles deposit.



**Figure.2** H&E staining of pouch tissues. B, implanted bone; M, pouch membrane tissue.



**Figure. 3** TRAP<sup>+</sup> cells are reduced by CL2MDP treatment. This figure showed the representative TRAP staining in paraffin tissue sections. (x200). TRAP was stained dark red and indicated by arrowheads. B, implanted bone; M, pouch membrane tissue.



## Discussion & Conclusion:

Our study has demonstrated that macrophage depletion using CL2MDP reduces UHMWPE particle- induced tissue inflammation, and osteoclast formation. This observation supports the hypothesis that macrophages contribute to the severity of UHMWPE particles induced inflammatory osteolysis. Macrophages represent a potential therapeutic target in the prevention and treatment of patients with total joint replacement.