

Posterolateral Fusion in a New Zealand White Rabbit Model

¹B. Schlossberg, ¹W. Lloyd, ²R. Oliver, ²C. Christou, ²A. Low, ²Y. Yu, ²N. Bertollo, ²W.R. Walsh

¹Pioneer Surgical, Marquette, MI

²Surgical & Orthopaedic Research Laboratories, University of New South Wales, Sydney, Australia;

Statement of Purpose: Autograft harvested from the iliac crest or local bone is considered the gold standard for bone grafting procedures. Inherent disadvantages with autograft include limited supply, increased operating time and donor site morbidity. This study utilized a challenging model of posterolateral fusion to evaluate the in vivo response to an engineered collagen carrier combined with nano-structured hydroxyapatite (NanOss[®] Bioactive 3D, Pioneer Surgical) compared to a collagen porous beta-tricalcium phosphate bone void filler (Vitoss[™] BA, Stryker).

Methods: A single level posterolateral fusion was performed in 72 adult rabbits¹ and evaluated at 6, 12 and 26 weeks (8 per group per time point). Group 1: NanOss Bioactive 3D + bone marrow aspirate (BMA) + Autograft, Group 2: Vitoss BA + BMA and Group 3: Autograft + BMA. Bone marrow aspirate was harvested from the proximal tibia. Morcelized Autograft cortico-cancellous bone was harvested from the iliac crests was mixed prior to implantation on each side (1.5 cc per side) over the decorticated transverse processes. Groups were compared using radiographic (X-ray and Micro-computed tomography (μ CT), biomechanics (manual palpation and tensile testing at 12 and 26 weeks) and histology (paraffin and PMMA).

Results: Radiographic grading and μ CT (Fig 1) demonstrated progressive increases in radiopacity at the transverse processes and at the middle of the developing fusion for Groups 1 and 3. New bone formation was noted for Group 2 only at the transverse processes (not in the middle of the fusion site).

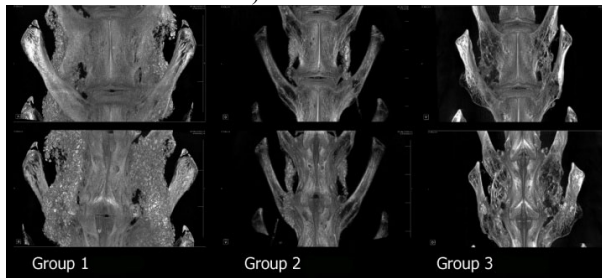


Figure 1: Micro CT models fusion sites at 26 weeks.

Manual palpation revealed comparable fusion rates in Groups 1 and 3 (43% and 38%, respectively). None of the animals from Group 2 were fused by manual palpation. Group 3 outperformed Group 2 ($P < 0.05$) while the results were similar to Group 1. Histological on the transverse processes at 6, 12, and 26 weeks (Fig 2) demonstrated an

osteochonductive response with woven bone formation and subsequent remodeling for all groups. Histology in the

middle of the fusion mass (between the transverse processes) also demonstrated an osteochonductive response with remodeling and the development of marrow spaces in the Groups 1 and 3 at 6, 12, and 26 weeks. Bone formation in the middle of the fusion was negligible at 6, 12 and 26 weeks for Group 2.

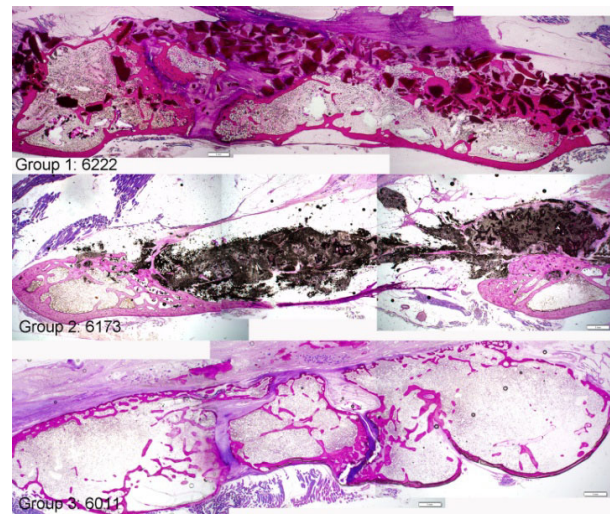


Figure 2: PMMA histology of fusion mass at 26 weeks.

Conclusions: Posterolateral fusion models represent an extremely challenging biological site to evaluate bone graft materials and provide insight into clinical performance. Graft materials must perform not only on the decorticated host bone but between the transverse process to achieve fusion between the treated levels.

Group 1 (NanOss Bioactive 3D + Autograft + BMA) performed well in the current model providing an osteochonductive scaffold that supported new bone formation on the transverse processes as well as in the middle of the fusion mass and that remodeled with time based on all endpoints. The nano-structured hydroxyapatite material in the NanOss Bioactive 3D resorbed with time but had yet to completely resorb at 26 weeks. Group 2 (Vitoss BA + BMA) performed well on the transverse processes in terms of new bone formation however new bone in the middle of the fusion mass was negligible at 6, 12, and 26 weeks. Group 3 (Autograft + BMA) performed well with new bone formation and remodeling on the transverse process and in the middle of the fusion mass as well as is consistently reported with this model.

References:¹ Walsh WR, et al; Eur Spine J. 2009 November; 18(11): 1610-1620² Boden SD, et al. Spine; 1999 Feb 15; 24(4):320-7.