

Evaluation of Magnesium Alloys for Use as Degradable Stents in a Rat Trachea Bypass Model

Sarah Luffy^{1,2}, Da-Tren Chou^{1,2}, Jingyao Wu^{1,2}, Peter D. Wearden^{1,3}, Kimi Tobita¹, Prashant N. Kumta^{1,2}, Jenora Waterman⁴, Thomas W. Gilbert^{2,5}

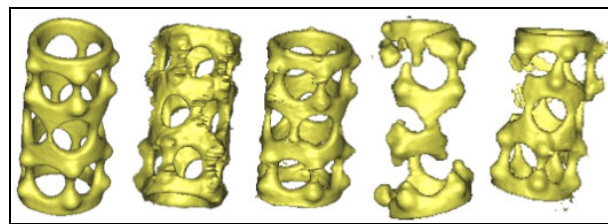
¹McGowan Institute for Regenerative Medicine, ²University of Pittsburgh Department of Bioengineering, ³Children's Hospital of Pittsburgh Department of Cardiothoracic Surgery, ⁴North Carolina A&T University Department of Animal Sciences, ⁵ACell Inc. Columbia, MD.

Statement of Purpose: Tracheal stenting is used for successful management of adult airway obstructions, including tracheal stenosis, a narrowing of the tracheal lumen due to trauma or prolonged intubation. The permanent nature of non-degradable tracheal stents makes them a treatment option of last resort for pediatric patients. Complications associated with stent removal and restenosis could be avoided with degradable tracheal stent placement. Magnesium alloys have shown promise as degradable materials in orthopedic and cardiovascular applications, however the performance of magnesium alloys in the trachea remains unknown. This research explores three commercially available magnesium alloys for evaluation as degradable tracheal stents in a rat tracheal bypass model.

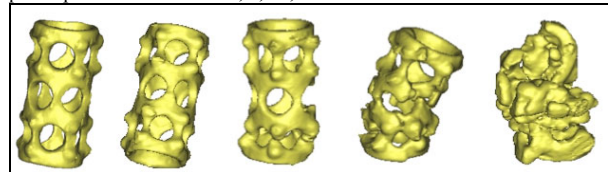
Methods: 99.9% pure magnesium (Goodfellow), AZ31 (Goodfellow), and W3 (Helmholtz Zentrum Geesthacht Institute of Materials Research, Geesthacht, Germany, provided as a gift from Dr. Norbert Hort and Dr. Frank Witte) were evaluated in this study. All three materials were T4 heat treated at 525 °C under a protective environment of Ar + 0.1% SF₆ for 8 h to homogenize intermetallics and alloying elements in the alloy matrix. Stents were machined to an outer diameter of 2.25mm, inner diameter of 1.25mm and length of 5mm. A second heat treatment was performed at 205°C for 1.5h in ultra high purity argon (UHP-Ar). All stents were sonicated in isopropanol for 5 minutes and dried in air (3x), and terminally sterilized with 2MRad γ -irradiation. Donor female lewis rats were sacrificed and the tracheas harvested to provide a bypass graft for stent evaluation. Recipient animals were anesthetized by intraperitoneal injection of ketamine (80 mg/kg) xylazine (8 mg/kg) to maintain the surgical plane of anesthesia. The ventral cervical trachea was accessed through a midline neck incision. Small (1mm x 1mm) proximal and distal defects separated by 5 cartilage rings were created in the recipient trachea. The stent was placed intraluminally in the donor trachea, which was anastomosed to the distal and proximal defects using 7-0 prolene suture (Ethicon, Somerville, NJ) in and end to side fashion. The surgical site was closed using an interrupted suturing technique with 5-0 PDS suture (Ethicon, Somerville, NJ). Animals were euthanized at 1, 8, 16, and 24 weeks for evaluation by μ CT and standard histologic analysis. In addition, identical stents were exposed to continuous flow of saline or simulated airway fluid in a custom bioreactor for 1 week, and the corrosion kinetics were analyzed by μ CT and compared to in vivo results.

Results: All animals survived to the predetermined end points. Histological analysis revealed a mild inflammatory response to the magnesium stents. Results varied among alloy type and time point, but the presence of a ciliated epithelium in the stented trachea was

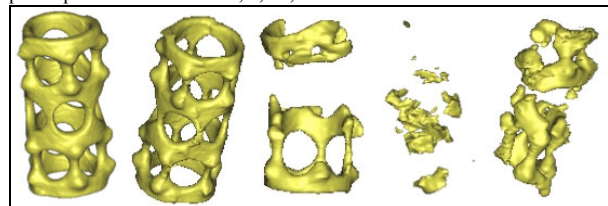
revealed by 8 weeks and persisted at 24 weeks. Airway patency was maintained in both the graft and the native trachea with communication maintained. MicroCT imaging of the alloys revealed significant differences in total stent volume lost over time in vivo. The 99.9% pure magnesium stent experienced greater corrosion than the magnesium alloys during both in vitro and in vivo testing. In vivo corrosion results were compared to in vitro results, which revealed greater stent corrosion in saline control media when compared to simulated airway fluid. No significant differences were found between total stent volume lost in vivo and in vitro.



Pre-Implant 1 week 8 weeks 16 weeks 24 weeks
Figure 1. MicroCT images of AZ31 magnesium tracheal stent shown at pre-implantation and after 1, 8, 16, and 24 weeks in vivo.



Pre-Implant 1 week 8 weeks 16 weeks 24 weeks
Figure 2. MicroCT images of MgY magnesium tracheal stent shown at pre-implantation and after 1, 8, 16, and 24 weeks in vivo.



Pre-Implant 1 week 8 weeks 16 weeks 24 weeks
Figure 3. MicroCT images of 99.9% pure magnesium tracheal stent shown at pre-implantation and after 1, 8, 16, and 24 weeks in vivo.

Conclusions: Magnesium alloys exhibit potential for use as degradable intraluminal stents for tracheal obstructions. A ciliated epithelium was maintained even after 24 weeks in vivo. The in vivo corrosion results correlate to the in vitro corrosion results from the simulated airway media. Future plans for clinical translation should include an optimized geometry for an intraluminal tracheal stent, as well as evaluation of different magnesium alloys.

Acknowledgments: PNK and TWG would like to acknowledge the financial support of the National Science Foundation (CBET-0933153), Engineering Research Center-Revolutionizing Metallic Biomaterials (RMB) through grant-EEC-0812348.